



## PATHOLOGICAL CHANGES AND LOCAL DEFENSE REACTION OCCURRING IN SPONTANEOUS HEPATIC COCCIDIOSIS IN RABBITS (*Oryctolagus cuniculus*)

Darzi M.M.\*, Mir M.S.\*, Kamil S.A.\*, Nashiruddullah N.\*, Munshi Z.H.†

\*Div. of Veterinary Pathology. †Div. of Public Health. Fac. of Veterinary Sci. and Animal Husbandry.  
S.K. Univ. of Agricultural Sci. and Tech. of Kashmir, KASHMIR, India.

**ABSTRACT:** Hepatic coccidiosis occurred in 56 rabbits belonging to different ages, sexes and breeds during the years from 2002 to 2005. Clinically, the severely affected rabbits showed decreased growth rate, anorexia, debilitation, listlessness, diarrhea, icterus and rough hair coat. Postmortem examinations revealed increased dirty dull straw colored peritoneal fluid. Hepatomegaly, with presence of discrete yellowish-white nodules of 1mm to 1 cm size on the surface and throughout the parenchyma, was seen. Smears from peritoneal fluid showed rafts of mesothelial cells. Impression smears from the liver nodules revealed presence of numerous developmental stages of *Eimeria stiedae* corresponding with the stage of the liver lesion. These were intermixed with sheets of hepatobiliary cells and inflammatory cells and the changes were reflective of the histological changes like biliary hyperplasia, cholangitis and vacuolar changes occurring in the liver. There was increase in the thickness of basement membrane with the advanced stage of the lesion. The basement membrane was up to 1-2  $\mu\text{m}$  in thickness forming loop like structures over which resided hyperplastic biliary cells containing different stages of the parasite. Some thickened basement membranes were devoid of overlying cells which had desquamated and were present in the ductal lumens suggesting that the basement might have the local defensive role in warding off the coccidial infection. The basement membrane was positive for neutral mucopolysaccharides while as the inflammatory zones and biliary epithelia along with the gametogonic stages of the coccidium reacted positively to the increased acid mucopolysaccharides qualitatively. The results showed that the occurrence of hepatic coccidiosis in female rabbits coincided with the breeding and kindling periods. Direct wet mount smears from bile aid in diagnosis of the disease. Impression smears from the liver nodules might represent the histological changes in the liver. The basement membrane thickening might have a defensive role in warding off the coccidial infection.

**Key words:** Rabbits, hepatic coccidiosis, *Eimeria stiedae*, pathology, local defense.

### INTRODUCTION

Rabbit farming, for fur and meat production, has emerged as an important livestock enterprise in many parts of temperate and subtropical areas of India, especially the North Eastern region, Himachal Pradesh, Uttar Pradesh, Uttaranchal, Jammu and Kashmir, Tamil Nadu, Kerala and Karnataka. It offers profitable returns because of their early maturity, prolific breeding and shorter gestation period. Further rabbit wool is of superior quality as compared to sheep wool and has better insulation properties. The average wool production of an Angora rabbit varies from 800-1000 g in a year while a broiler rabbit produces about 4 kg of meat (Gupta, 2005). The profitability of the rabbit industry is dependent primarily on good feed conversion (Varga, 1982). The remuneration from this enterprise is greatly decreased owing to susceptibility of the rabbits to various diseases.

Correspondence: M.M. Darzi, darzi\_maqbool@rediffmail.com  
Received March 2006 - October 2006.

Amongst the parasitic diseases, coccidiosis is of particular importance in commercial rabbitry. It is a highly contagious sporozoal infection in rabbits and is caused by a protozoan parasite, *Eimeria* species which are highly host, organ and tissue specific (Levine, 1985; Georgi and Georgi, 1990). Coccidiosis in rabbits in the hepatic form is caused by *E. stiedae*, and the intestinal form is caused by several *Eimeria* species (Fox *et al.*, 1984). Rabbit is the only animal that suffers from hepatic form of coccidiosis leading to severe economic losses. By far, to the authors' knowledge, there have not been any documented reports of hepatic coccidiosis in rabbits of Kashmir valley. The present communication, based on a four-year retrospective study, records spontaneous hepatic coccidiosis in various breeds of rabbits at necropsy, and attempts to elucidate their histopathological findings vis-à-vis local defense response.

## MATERIAL AND METHODS

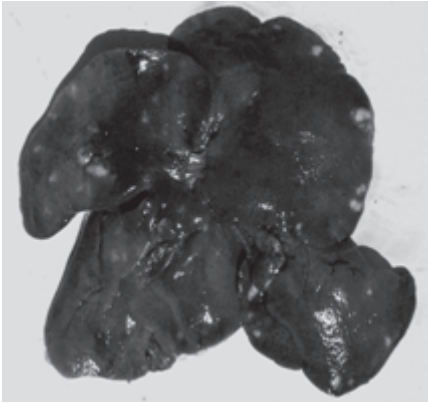
Fifty-six rabbits, received by Division of Veterinary Pathology for postmortem examination from the University Rabbit Farm, were found to be affected with hepatic coccidiosis during the years 2002 to 2005. The animals belonged to Angora, New Zealand and Grey Giant breeds and comprised of males and females of varying ages- ranging from less than a month old to over 2 years. Clinical history and gross lesions at necropsy were recorded of each animal over the period. Smears were prepared from the peritoneal fluid and gall bladder aspirate. Impression smears were made from the cut surface and crushed nodules of the liver. These were stained with modified Wrights stain (Benjamin, 1981). Representative tissue samples from the liver, gall bladder and various other organs were collected in 10% formol saline. These were processed for routine histopathological observations. Five micron thick tissue sections were stained with Harris' haematoxylin and eosin (Luna, 1968). Triplicate sections were stained with periodic acid-Schiff (PAS) (McManus, 1946), combined alcian blue-PAS techniques and Masson's Trichrome stains (Luna, 1968) for demonstration of basement membrane, acid and neutral mucins, and fibroplasia respectively. The thickness of the basement membrane was measured in PAS stained section using an ocular micrometer under an oil immersion objective.

## RESULTS

Clinically, the severity of lesions present at necropsy correlated with overt signs. Those rabbits with a history of no apparent symptoms except for a decreased growth rate had relatively less severe lesions at necropsy. Those that had been affected with pronounced lesions were associated with anorexia, debility, listlessness and a rough hair coat. Some rabbits were found with a distended abdomen, diarrhea with soiling of hind quarters, and were jaundiced. The back and hind quarters in some showed pronounced muscle wasting.

Lesions included hepatomegaly with presence of discrete yellowish-white nodules of varying sizes (1 mm to 1 cm) diffusely spread over its surface and in the parenchyma (Figure 1). The organ was either pale or severely congested. The nodular exudes expressed on pressing were either milky or thick cheesy. The gall bladders were distended with thick green bile. Lungs appeared congested and oedematous in most cases. The kidneys were mostly enlarged and congested. Postmortem examination of ascites cases revealed dirty straw colored peritoneal fluid.

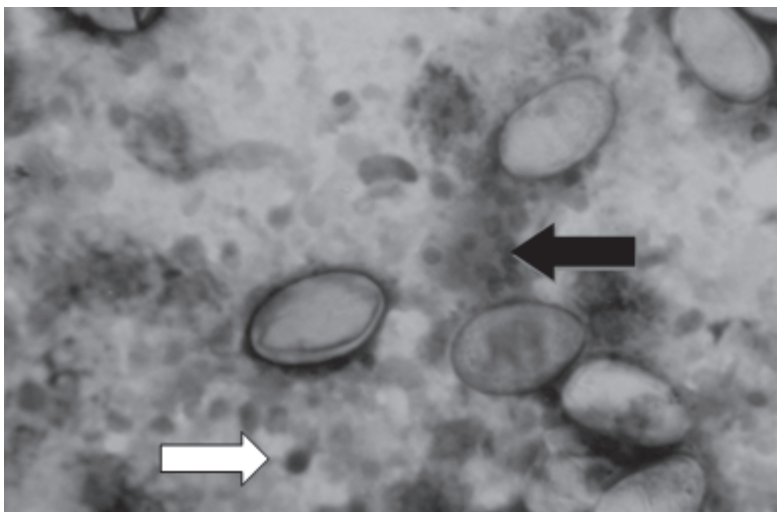
Wet mounts from gall bladder aspirates revealed presence of numerous oocysts of *Eimeria stiedae* that appeared ovoid and containing developing embryos. Some of oocysts were deeply brown in color. The oocysts dimensions from the aspirates ranged approximately between 18 to 24  $\mu\text{m}$  in width and 30 to 39  $\mu\text{m}$  in length, with a flat micropylar end and a smooth bright pinkish wall. Smears prepared from peritoneal fluid aspirates showed rafts of mesothelial cells. Press preparations from the smaller nodules of the affected liver showed presence of numerous schizonts. The larger nodules revealed numerous coccidial oocysts often with a wrinkled wall and intermixed with hepatobiliary



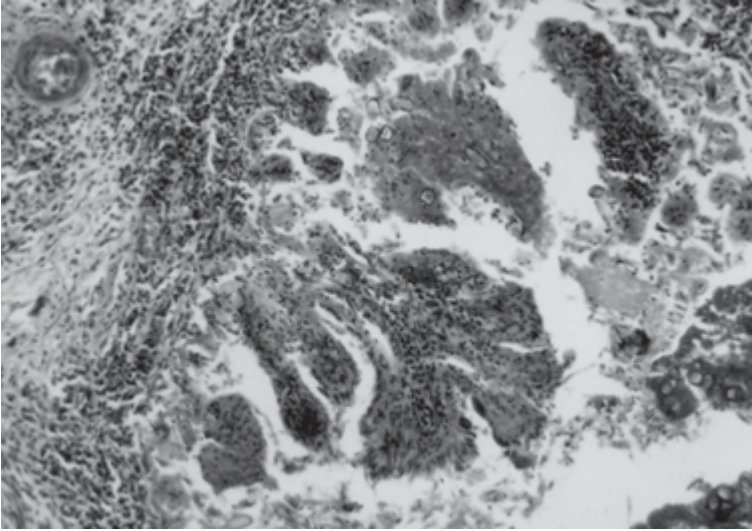
**Figure 1:** Liver of a rabbit affected with hepatic coccidiosis showing yellowish-white nodules of varying sizes in the liver.

and inflammatory cells (Figure 2). Macrogametes appeared rounded or oval, ranging from 20 to 23  $\mu\text{m}$  in width and 25 to 34  $\mu\text{m}$  in length, and filled with homogeneous pink to bluish cytoplasmic granules with a row at the periphery, referred to as the wall forming bodies. The microgametocytes were distinguishably large and rounded, measuring up to 45  $\mu\text{m}$  in diameter, and filled with a large number of purple round to comma shaped microgametes. Sheets of cuboidal to columnar bile duct epithelial cells were present. Hepatocytes revealed vacuolar degeneration with some cells showed greenish pigments.

Histopathologically, the bile ducts were greatly thickened and distended. Biliary hyperplasia was evident and characterized by the formation of multiple arborizing papillary fronds extending into the ductal lumens, resembling adenomatous hyperplasia (Figure 3). The core and wall of the ducts were infiltrated with mononuclear cells. Further, the ducts were filled with sloughed biliary epithelial cells and numerous coccidial oocysts and developmental stages of the coccidium. The biliary mucosa revealed cyst-like spaces and the hyperplastic ducts were surrounded with large amounts of connective tissue. Portal spaces were filled with mononuclear cells. The basement membrane was

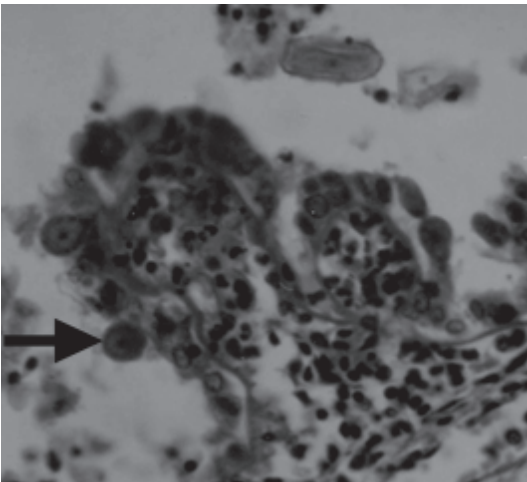


**Figure 2:** Impression smear from the hepatic nodule revealing numerous coccidial oocysts. Some of the oocysts are wrinkled because of drying and fixation. Clusters of epithelial cells (black arrow) and numerous mononuclear cells are seen between the oocysts (white arrow). Modified Wrights Stain X 40.

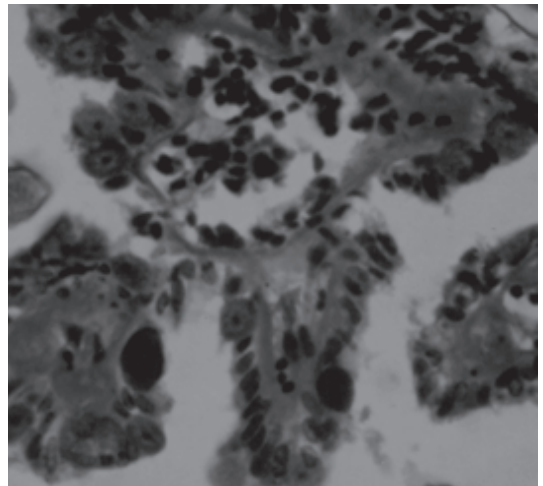


**Figure 3:** Section of a liver affected with hepatic coccidiosis showing formation of papillary fronds projecting into the dilated ductal lumen. H&E X 10.

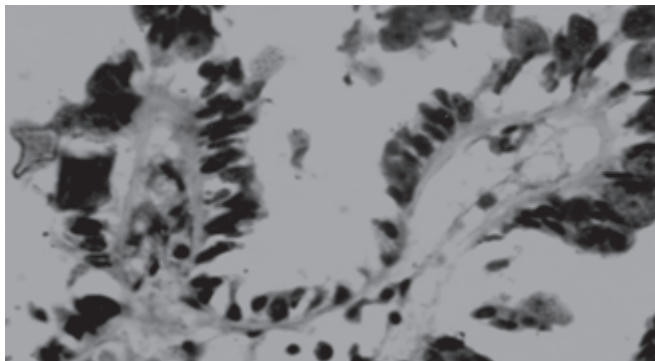
thickened and was about 1 to 2  $\mu\text{m}$  in thickness. It was either lining the ducts with its superficial cells sloughed off or had evaginated into the ductal lumen in a fold like manner bearing the cells containing dull brownish macrogametes with wall forming granules at their periphery (Figure 4). The fold of basement membrane formed the loop-like structure, which seemed to get detached from the wall along with the overlying coccidian contained epithelial cells and were found in the lumens of ducts (Figure 5). The developmental stages of coccidian and inflammatory exudates were positive for qualitative increase in acid mucopolysaccharides whereas the basement was positive for neutral mucopolysaccharides (Figure 6). The lungs and kidneys revealed congestion and cellular swelling and vacuolar degeneration of the parenchymal cells.



**Figure 4:** Section of liver affected with hepatic coccidiosis revealing looping in of thickened basement membrane over which reside the epithelial cells containing macrogametocytes (arrow). PAS X 10



**Figure 5:** Section of liver affected with hepatic coccidiosis showing detachment of the looped basement membrane along with biliary epithelium which contain the developmental stages of coccidia. PAS X 10.



**Figure 6:** Section of liver affected with hepatic coccidiosis revealing biliary epithelium positive for acid mucopolysaccharides while basement membrane is positive for neutral mucopolysaccharides. Combined alcian blue PAS technique X 10.

## DISCUSSION

Coccidiosis in rabbits is seen as hepatic coccidiosis caused by *Eimeria stiedae* and intestinal coccidiosis caused by *E. intestinalis*, *E. irresidua*, *E. magna*, and *E. media* (Bhatia, 2000). Hepatic coccidiosis in rabbits occurs due to ingestion of sporulated oocysts having four ovoid sporocysts containing 2 sporozoites each. The sporozoites penetrate the mucosa of small intestine and pass via the mesenteric lymph nodes and hepatic portal system to the liver where they enter the epithelial cells of the bile duct becoming trophozoites and then schizonts. The carbohydrate L-fucose residues on *E. stiedae* sporozoites and L-fucose-binding sites on host cells might have helped in recognition and/or invasion process (John *et al.*, 1999). The schizonts produce merozoites, but the number of asexual generations preceding gametogony is unknown. Oocysts pass out in the bile and appear in the faeces 18 days after infection, sporulation occurs in three days (Flynn, 1973; Urquhart *et al.*, 1987; Barriga, 1997; Gardiner *et al.*, 1998).

There was an increase in the thickness of the basement membrane indicating its involvement in the pathogenesis of the pseudopapillomatosis. The base membrane serves as a limiting substratum to support the overlying epithelium. The large branching hyperplastic epithelium was thought to need a comparatively thicker basement membrane for its support (Chen *et al.*, 1972). In the opinion of authors the thickened basement membrane appears to be a defensive act on part of the host against coccidial infection. A thickened basement membrane could impede the transfer of essential nutrients to the overlying epithelium and can in turn induce regression and degeneration of a hyperplastic epithelium. This was amply evidenced by absence of overlying epithelia in certain areas of thickened basement membrane. Further, the evagination of basement membrane in the form of loop-like structures and subsequent detachment of this loop along with the overlying hyperplastic epithelium supports the view that basement membrane has a role in defence mechanism. Detached basement membrane structures were seen in the lumens of the ducts thereby shedding the epithelium containing developmental stages of the coccidian. Besides, the existence of a basement membrane seems to facilitate the orientation of the newly formed epithelial cells in the epithelialisation process (Giacometti and Parakkal, 1969) and its role in warding off the infection is possible. The increased acid mucopolysaccharide in the areas might be the result of inflammatory process. It has been suggested that glycosaminoglycan, hyaluronic acid, is involved in the pathogenesis of liver diseases and its increase in the liver and serum has been used as a reliable marker of hepatic fibrosis and fibrogenesis (Frebourg *et al.*, 1986; Murawaki *et al.*, 1996; Peres *et al.*, 1996; George *et al.*, 2004).

The smears from the liver nodules were reflective of the histological observations in the liver as evidenced by presence of sheets of hyperplastic biliary epithelial cells, developmental stages of oocysts and inflammatory cells. The desquamation of mesothelial cells and development of increased peritoneal fluid could be the result of liver damage.

As the coccidial oocysts are shed with the faeces contaminating the environment, food and water the rabbit's cages, food dishes and water containers need to be routinely disinfected. Avoidance of stress and strict sanitary measures are thought to reduce or prevent clinical disease (Fox *et al.*, 1984).

## REFERENCES

- Barriga O.O. 1997. The class Apicomplexa or Sporozoa. In: *Veterinary Parasitology for Practitioners, 2nd edition, Edina, Minn: Burgess International Group*, 76.1-26.4.
- Benjamin M.M. 1981. Outline of Veterinary Clinical Pathology, the Iowa State University Press Ames, Iowa, USA, 30.
- Bhatia B.B. 2000. Textbook of Veterinary Protozoology. 1st edition. *Directorate of Information and Publication of Agriculture, Indian Council of Agricultural Research, Krishi Anusandhan Bhavan, Pusa, New Delhi, 178-180.*
- Chen C.M.C., Tsai L.C., Chung C.F., Han, S.H. 1972. Basement membrane in hepatic coccidiosis of rabbits. *J. Camp. Pathol.* 82, 59-63.
- Flynn R.J. 1973. Protozoans and neosporans. In: *Parasites of Laboratory Animals, Ames, Iowa, Iowa State University Press*, 54-56.
- Fox J.G., Cohen B.J., Loew F.M. 1984. *Laboratory Animal Medicine. Academic Press Inc. (London) Ltd.*, 222-224.
- Frebourg T., Delpech B., Bercoff E., Senant J., Bertrand P., Deugnier Y., Bourreille J. 1986. Serum hyaluronate in liver diseases: study by enzymeimmunochemical assay. *Hepatology* 6, 392-405.
- Gardiner G.H., Fayer R., Dubey J.P. 1998. Apicomplexa. In: *An Atlas of Protozoan Parasites in Animal Tissues, 2nd edition, Armed Forces Institute of Pathology, Washington, DC.*, 20-30.
- Georgi J.R., Georgi M.E. 1990. Protozoans. In: *Parasitology for Veterinarians, 5th edition, W.B. Saunders, Philadelphia*, 34-87.
- George J., Tsutsumi M., Takase S. 2004 Expression of hyaluronic acid in N-nitrosodimethylamine induced hepatic fibrosis in rats. *Int. J. Biochem. Cell Biol.* 36, 307-319.
- Giacometti L., Parakkal P.F. 1969. Skin transplantation: Orientation of epithelial cells by the basement membrane. *Nature*, 223, 514-515.
- Gupta V.K. 2005 Pathology of naturally occurring rabbit diseases in Himachal Pradesh. In: *Souvenir-XXII Annual Convention of Indian Association of Veterinary Pathologists and National Symposium on Newer Concepts in Animal and Avian Disease Diagnosis-A Farmer, Industry and Institutional Dialogue and a satellite Seminar on Principles of Histological Basis of Gross Pathology of CL Davis DVM Foundation, USA. November. 193-204.*
- John N.M., Zea M.E., Kawano T., Omata Y., Saito A., Toyoda Y., Milkano T. 1999. Identification of carbohydrates on *Eimeria stiedae* sporozoites and their role in the invasion of cultured cells in vitro. *Vet. Parasitol.* 81, 99-105.
- Levine N.D. 1985. Apicomplexa- The Coccidia Proper. In: *Veterinary Protozoology, Iowa State University Press, Ames, Iowa*, 130-138, 178, 221-222.
- Luna L.G. 1968. Manual of Histologic Staining Methods of the Armed Forces Institute of Pathology, 3rd edition. McGraw-Hill Book Company, New York, USA, 38-39, 94-95, 168-169.
- Mc Manus J.F.A. 1946. Histopathological demonstration of mucin after periodic acid. *Nature (London)*, 158, 202, in: *BANCRAFT, J.D. and GAMBLE, M (ed), 2002. Theory and practice of histopathological techniques, 5th edn, Churchill Livingstone, London, Edinburgh, New York, Philadelphia, St. Louis, Sydney, Toronto, 175.*
- Murawaki Y., Ikuta Y., Koda M., Nishimura Y., Kawasaki H. 1996. Clinical significance of serum hyaluronan in patients with chronic viral liver disease. *J Gastroenterol. Hepatol.* 11, 459-465.
- Peres A., Deulofeu R., Gimenez A., Caballeria L., Bruguera M., Caballeria J., Ballesta A.M., Rodes J. 1996. Serum hyaluronate reflects hepatic fibrogenesis in alcoholic liver disease and is useful as a marker of fibrosis. *Hepatology* 24, 1399-1403.
- Urquhart G.M., Armour J., Duncan J.L., Dunn A.M., Jennings F.W. 1987. Phylum Protozoa. In: *Veterinary Parasitology, Churchill Livingstone, New York*, 218-220.
- Varga I. 1982. Large scale management systems and parasite populations: coccidian in rabbits. *Vet. Parasitol.* 11, 69-84.